

Highly diluted medication modifies parasitological, immunological and histopathological parameters of *Trypanosoma cruzi* infection

Denise Lessa Aleixo, Franciele Karina da Veiga, Larissa Ciupa, Angela Rigo Portocarrero, Patricia Flora Sandri, Fabiana Nabarro Ferraz, Mateus Joacir Benvenuto, Silvana Marques de Araújo

Universidade Estadual de Maringá – UEM, Paraná, Brazil

Background: The murine model of infection by *T. cruzi* progresses acutely with inflammation and tissue parasitism, mainly in the heart and the pattern of resistance or susceptibility are related to the type of cytokine produced [1].

Aims: Evaluate parasitological, histological and immunological parameters in animals infected by *T. cruzi*, treated with highly diluted medication (200DH *T. cruzi*-biotherapy) in different schedules.

Methodology: A blind randomized controlled trial was performed using swiss male mice, aged 56 days-old, divided into groups: NI- noninfected mice; infected mice treated with: CI- 7%water-alcohol solution; OD - 200 DH *T. cruzi* in a single day; ED -200 DH *T. cruzi* from infection until the end of the experiment. The groups were infected with 1400 blood trypomastigotes Y strain-*T.cruzi*, intraperitoneal. Medicine was handled according to the Brazilian Homeopathic Pharmacopoeia, with microbiological testing (RDC nº 67-MSBrazil [2]) and in vivo biological test negative. Medicine was administrated diluted in water (1mL/100mL). Parasitological parameters and mortality were evaluated daily. Organs and serum was collected at 0, 4th, 8th and 12 th days of infection. Cytokine profile was assessed using BD Cytometric Bead Array Mouse Th1/Th2/Th17-Cytokine Kit and histopathological parameters were evaluated in histological sections (hematoxylin-eosin). The data were compared using Statistica 8.0, 5% significance. Approved by the Ethics Committee for Animal/UEM.

Results: The use of the highly diluted medication *T.cruzi* 200dH increased total parasitemia and the number of nests of amastigotes. The increase was significant ($p < 0.05$), on the 12th day of infection, in liver and spleen to the ED group and heart, intestine, liver and spleen to the OD group, compared with the CI group. There was no significant difference between groups ED and OD. In group OD observe an attempt to contain the inflammation in the assessment of inflammatory foci, with fewer fields with diffuse inflammation overall and a greater number of fields containing focal inflammation, especially in the cardiac tissue. In contrast, the ED group showed an increase in the number of fields with diffuse inflammation overall. In histopathological comparison OD group showed better performance compared with the ED group ($p < 0,05$). Considering cytokines analysis treated animals showed decreased production of INF γ , TNF α , IL-10, IL-17A, more accentuated in group ED group. The imbalance of cytokines observed in these groups explains the increase of parasitemia and inflammation observed mainly in the ED group.

Conclusion: Considering parasitological, immunological and histopathological aspects, this study confirms clinical practice, where medicines are not recommended at higher potencies, administered at daily doses for acute illnesses.

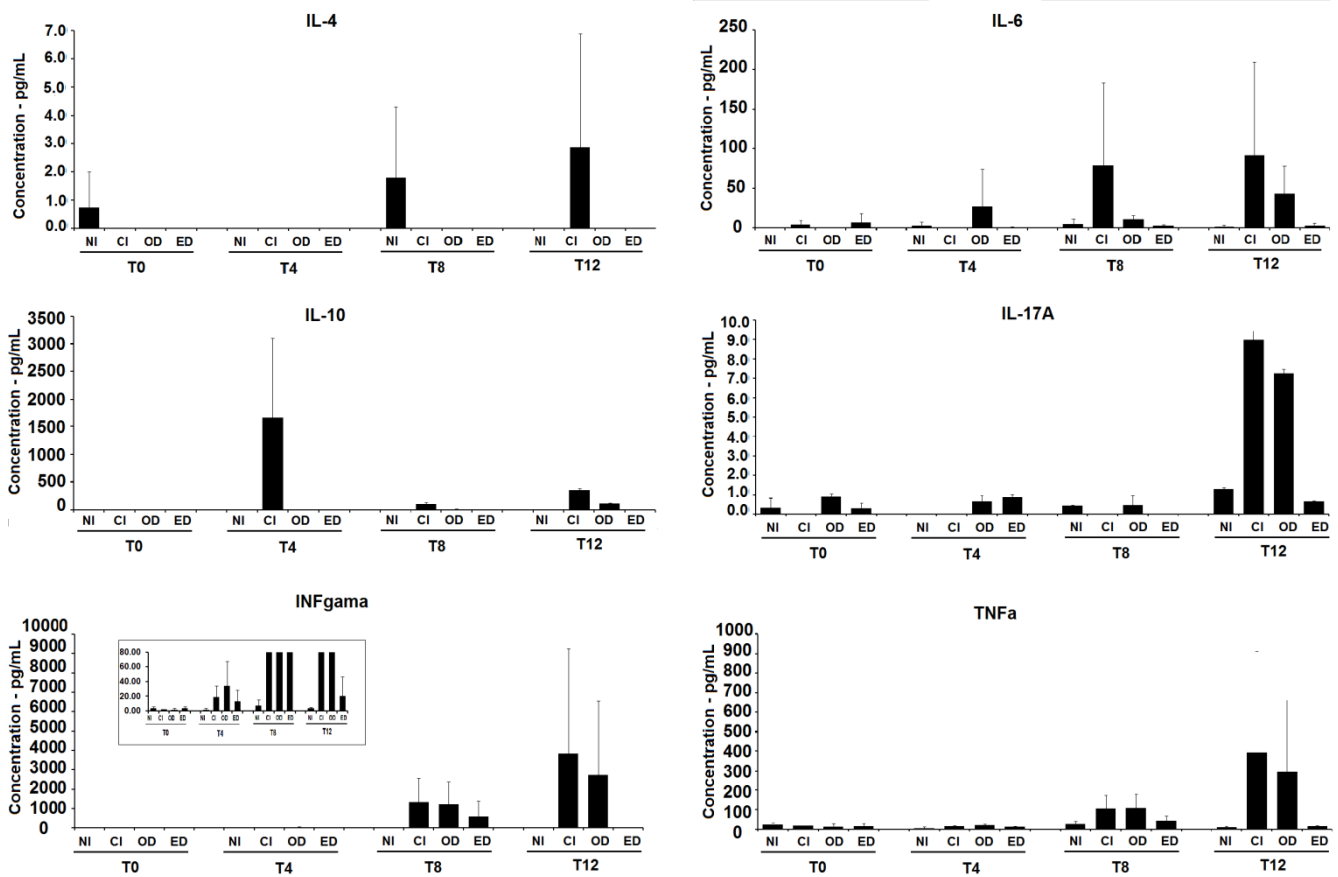


Figure 1. Concentrations (pg/mL) of different cytokines (IL-4, IL-6, IL-10, IL-17A, INFgama e TNFα) of serum of animals treated with 200 DH *T. cruzi* medication in different times and schedule of treatment.

Reference

- [1] Telleria, J., Tibayrenc, M., (Eds.), American Trypanosomiasis Chagas Disease: one hundred year of research. Elsevier Inc., London. 2010.
- [2] Brasil, Ministério da Saúde. 2007. Resolução da Diretoria Colegiada - RDC N° 67. Diário Oficial da União, Brasília (DF). 8 de outubro de 2007. Highly diluted medication modifies parasitological, immunological and histopathological parameters of *Trypanosoma cruzi* infection.



Licensed to [GIRI](http://www.giri.org.br)

Support: Fundação Araucária, CAPES and CNPq

Conflict of interest: authors declare there is no conflict of interest

Received: 16 June 2013; Revised: 12 August 2013; Published: 30 September 2013.

Correspondence author: Denise Lessa Aleixo, deniseparasito@gmail.com

How to cite this article: Aleixo DL, da Veiga FK, Ciupa L, Portocarrero AR, Sandri PF, Ferraz FN, Benvenutti MJ, de Araújo SM. Highly diluted medication modifies parasitological, immunological and histopathological parameters of *Trypanosoma cruzi* infection. Int J High Dilution Res [online]. 2013 [cited YYYY Month dd]; 12(44): 107-108. Proceedings of the XXVII GIRI Symposium; 2013 Sep 03-04; Bern (Switzerland). GIRI; 2013; Available from: <http://www.feg.unesp.br/~ojs/index.php/ijhdr/article/view/671/653>